

CONCISE COMMUNICATION

Bacterial Infection Promotes Colon Tumorigenesis in *Apc*^{Min/+} Mice

Joseph V. Newman,^{1,a} Takeo Kosaka,^{2,a}
 Barbara J. Sheppard,² James G. Fox,^{1,2}
 and David B. Schauer^{1,2}

Divisions of ¹Bioengineering and Environmental Health
 and ²Comparative Medicine, Massachusetts Institute
 of Technology, Cambridge

The Min mouse, which has a germ line mutation in 1 allele of the *Apc* tumor suppressor gene, is a model for the early steps in human colorectal cancer. *Helicobacter pylori* infection, a known risk factor for gastric cancer in humans, causes chronic inflammation and increased epithelial cell proliferation in the stomach. Infection with the bacterium *Citrobacter rodentium* is known to increase epithelial cell proliferation and to promote chemically initiated tumors in the colon of mice. Min mice infected with *C. rodentium* at 1 month of age were found to have a 4-fold increase in the number of colonic adenomas at 6 months of age, compared with uninfected Min mice. Most of the colonic adenomas in the infected Min mice were in the distal colon, where *C. rodentium*-induced hyperplasia occurs. These data demonstrate that bacterial infection promotes colon tumor formation in genetically susceptible mice.

Citrobacter rodentium is a naturally occurring bacterial pathogen of laboratory mice. *C. rodentium* infection is characterized by epithelial cell hyperproliferation similar to that seen in human idiopathic inflammatory bowel disease, including Crohn's disease and ulcerative colitis [1]. Individuals with these diseases are known to have an increased risk for, and early onset of, colorectal cancer. After natural infection or experimental inoculation with *C. rodentium*, suckling mice develop diarrhea and weight loss accompanied by significant mortality [2]. Affected animals develop proliferative colitis with thickening and rigidity of the distal colon. Adult mice develop severe but temporary colonic hyperplasia accompanied by expansion of the proliferative compartment and limited inflammation [2].

In mice experimentally inoculated with *C. rodentium*, hyperplasia is detectable as early as 4 days after inoculation, increases rapidly in severity through weeks 2 and 3, and resolves some 5–8 weeks after inoculation [2]. Colonic crypts from *C. rodentium*-infected mice are up to 3 times longer than those from uninfected control mice and contain more than twice as many dividing cells. [1]. The epithelial cell hyperproliferation that results from *C. rodentium* infection promotes the development of

colonic adenomas after administration of the carcinogen 1,2-dimethylhydrazine (DMH) [3]. "Promotion" in this sense refers to a reduced latent period, an increased incidence, and an increased number of tumors per animal. *C. rodentium* infection, in the absence of carcinogen administration, does not result in adenoma formation.

The mechanism by which *C. rodentium* infection induces mucosal hyperplasia is not fully understood. *C. rodentium* produces attaching and effacing (AE) lesions in the descending colon [4]. AE lesions are characterized by dissolution of the brush border, cupping of adherent bacteria by the cell membrane, and cytoskeletal rearrangements in enterocytes. AE lesions are also produced by the human pathogens enteropathogenic *Escherichia coli* (EPEC) and enterohemorrhagic *E. coli* (EHEC). Although other factors contribute to ileal attachment by EPEC and to extraintestinal complications with EHEC infection, such as hemolytic uremic syndrome, a 35-kb pathogenicity island called the locus for enterocyte effacement is required for AE lesion formation by *C. rodentium*, EPEC, and EHEC [4]. Infection of laboratory mice with *C. rodentium* has been used as a model system in which to study the contribution of AE lesion formation to infection and disease.

Apc^{Min/+} mice are heterozygous for the multiple intestinal neoplasia (Min) allele, which is a germ line nonsense mutation in the *Apc* tumor suppressor gene. Studies with Min and other *Apc* mutant mice have implicated this locus as a gatekeeper in intestinal tumorigenesis [5] and have helped to identify modifier genes that influence intestinal adenoma development. These animals also have been used to demonstrate the chemopreventive effect of cyclooxygenase (COX)-2 inhibitors on colon tumorigenesis [6], which, together with clinical studies, provides good evidence that COX-2 plays a causal role in colon carcinogenesis. To determine whether bacterial infection promotes

Received 2 October 2000; revised 5 April 2001; electronically published 18 June 2001.

All animal experiments were approved by the Massachusetts Institute of Technology Animal Care and Use Committee.

Financial support: National Institutes of Health (CA-76716 [fellowship to J.V.N.] and CA-63112 [grant to D.B.S.]).

^a Present affiliations: Triad Therapeutics, San Diego, California (J.V.N.); Department of Surgery II, Kanazawa Medical University, Uchinada, Ishikawa, Japan (T.K.).

Reprints or correspondence: Dr. David B. Schauer, MIT, Rm. 56-787B, Cambridge, MA 02139 (schauer@mit.edu).

The Journal of Infectious Diseases 2001;184:227–30

© 2001 by the Infectious Diseases Society of America. All rights reserved.
 0022-1899/2001/18402-0018\$02.00

colon tumors in this system, we infected Min mice with *C. rodentium*.

Materials and Methods

Animals. C57BL/6J *Apc*^{Min/+} (Min) mice were obtained from Jackson Laboratory. Male Min mice were mated with wild-type C57BL/6J *Apc*^{+/+} female mice. The mice were maintained in micro-isolator cages in a barrier facility and were given food and water ad libitum. Progeny were screened for the presence of the *Apc*^{Min} allele at 3 weeks of age, as described elsewhere [7]. Four-week-old mice were inoculated intragastrically with either 100 μ L of an overnight culture of *C. rodentium* ($\sim 1 \times 10^8$ cfu) or 100 μ L of sterile broth. Infection was confirmed by determining the number of colony-forming units of *C. rodentium* per gram of feces 7 days after inoculation. Eighteen Min mice and 12 wild-type mice were inoculated, and an equal number of uninoculated mice served as controls. Mice were euthanatized by CO₂ inhalation 10 days or 5 months after inoculation.

Gross pathology and histopathology. At necropsy, the intestinal tract from the pylorus to the anus was removed, opened lengthwise, and rinsed with PBS. The colon was examined for the presence of hyperplasia. The total number of adenomas, the diameter of each, and the location of each were recorded. Individual adenomas and tissue that appeared grossly normal from the colon, cecum, and ileum were fixed in 10% neutral buffered formalin, routinely processed, and embedded in paraffin. These tissues were sectioned at 4 μ m and were stained with hematoxylin-eosin for histologic analysis. In addition, representative samples were embedded in Glyofixx (Shandon) and were snap frozen in isopentane that had been cooled in liquid nitrogen.

Immunohistochemistry. Frozen tissue was serially sectioned at 5 μ m and was stained for vimentin, α -smooth-muscle actin, the macrophage marker F4/80, or COX-2. To block endogenous peroxidase activity, we treated sections with 3% H₂O₂ in methanol. Sections were incubated with normal serum from the appropriate animal species for 30 min and then with primary antibody for 1 h. Sections were rinsed with PBS and were incubated with secondary antibody conjugated to either alkaline phosphatase or horseradish peroxidase. Antibody complex was detected by use of the Vector Red Alkaline Phosphatase Substrate kit I (Vector Laboratories) or the DAB Reagent set (Kirkegaard & Perry) and was counterstained with hematoxylin. COX-2 was detected with a rabbit antimouse polyclonal antibody (Cayman Chemical), and α -smooth-muscle actin was detected by use of mouse IgG monoclonal 1A4 (Sigma), as described elsewhere [8]. Vimentin was detected by use of mouse IgM monoclonal 13.2 (Sigma), and F4/80 by use of rat IgG monoclonal A3-1 (Serotec).

Results

Colonic hyperplasia. Ten days after inoculation, 3 mice in each of the 4 groups were euthanatized and were examined for evidence of colonic hyperplasia. Both *C. rodentium*-infected Min mice and infected wild-type mice had developed profound thickening and rigidity in the distal colon by postinoculation

day 10 (figure 1A). The mean height (\pm SE) of the colonic crypt columns was not significantly different between infected Min and infected wild-type mice (54.8 ± 5.5 vs. 51.4 ± 3.6 cells, respectively; $P = .78$). Mean crypt column heights in infected Min and infected wild-type mice were significantly different from those in uninfected Min (25.6 ± 2.1 cells; $P = .001$) and uninfected wild-type (23.3 ± 2.0 cells; $P = .001$) mice.

Tumorigenesis. Five months after infection, adenomas were identified in both infected and uninfected Min mice. Histologically, the adenomas consisted of nodular areas of thickened mucosa that protruded into the colonic lumen. The base and lateral aspects of the tumors contained elongated glands lined by hyperplastic colonic epithelium (figure 1B). Although they contained highly dysplastic tissue (figure 1C), the tumors were considered adenomas rather than adenocarcinomas because they abutted but did not invade the muscularis mucosa.

Promotion by bacterial infection. *C. rodentium* infection of Min mice resulted in a significant increase in the number of colonic adenomas (2.8 ± 0.7), compared with the number in uninfected Min mice (0.8 ± 0.2 ; $P = .002$). No significant difference was seen in the total number of cecal or ileal adenomas (table 1). In addition, the mean distance of the colonic adenomas in *C. rodentium*-infected Min mice was more distal (16.6 ± 2.2 mm from the anus) than that in uninfected Min mice (30.4 ± 3.2 mm from the anus; $P = .001$). No adenomas were detected in infected or uninfected wild-type mice.

COX-2 expression. Antigen recovery using formalin-fixed tissue resulted in high levels of nonspecific staining of normal tissue with both the F4/80 and COX-2 antibodies, so immunohistochemistry was done on frozen sections. No COX-2 expression was seen in colonic sections from Min mice or wild-type mice on postinfection day 10, and none was seen in areas of the colon that appeared histologically normal 5 months after infection (data not shown). Colonic adenomas from both infected and uninfected Min mice labeled with COX-2 antibody. COX-2 antigen was localized to interstitial cells but not to epithelial cells (figure 1D and 1G). Although $\sim 10\%$ of COX-2-positive cells also labeled with F4/80 (figure 1E and 1H), most of the COX-2-positive cells did not appear to be macrophages. Furthermore, cells that were strongly positive for both COX-2 and α -smooth-muscle actin (figure 1F and 1I) were not observed. All of the COX-2-positive cells appeared to be vimentin positive (data not shown).

Discussion

There is growing recognition that infection with pathogenic bacteria can play a role in cancer risk. Infection with the bacterium *Helicobacter pylori* is a risk factor for gastric cancer [9]. *H. pylori* infection is known to cause chronic inflammation and to increase epithelial cell proliferation in the stomach. In addition, the related murine pathogen *H. hepaticus* has been

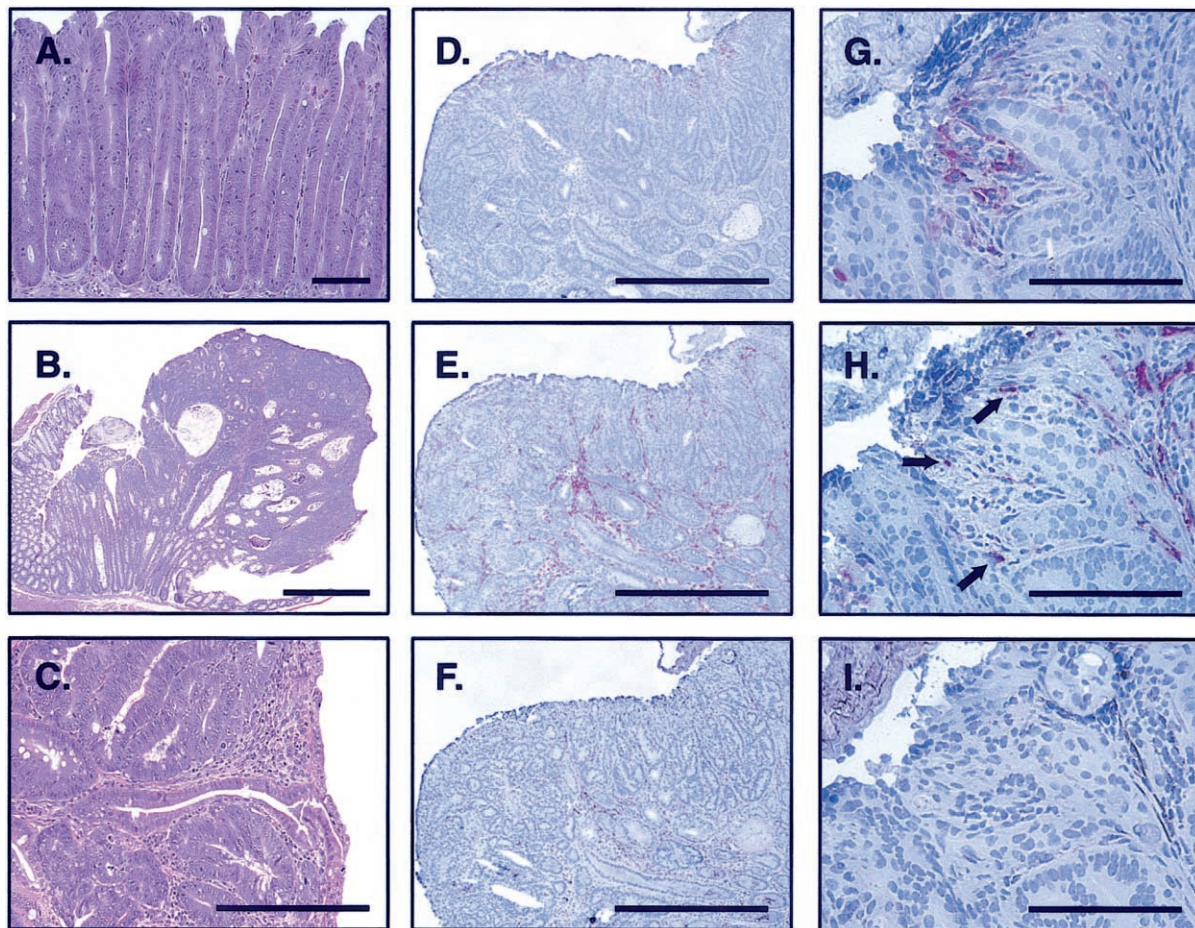


Figure 1. *A*, Hematoxylin-eosin stain of colonic tissue in *Citrobacter rodentium*-infected Min mouse, showing profound mucosal hyperplasia with loss of goblet cells and crowded, elongated crypts on postinoculation day 10 (original magnification, $\times 40$; bar, 100 μm). *B*, Colonic adenoma from infected Min mouse, showing an intact basement membrane and adjacent hyperplastic colonic epithelium (original magnification, $\times 20$; bar, 500 μm). *C*, Highly dysplastic tissue within a colonic adenoma (original magnification, $\times 200$; bar, 100 μm). *D–F*, Low-magnification images of a colonic adenoma from an infected Min mouse, showing COX-2- (*D*), F4/80- (*E*), and α -smooth-muscle actin- (*F*) positive cells (original magnification, $\times 40$; bars, 500 μm). *G–I*, High-magnification images of a region with COX-2-positive cells (*G*) from the same colonic adenoma, showing that some COX-2-positive cells colabel with F4/80 (*H*, arrows) but not with α -smooth-muscle actin (*I*) (original magnification, $\times 400$; bars, 100 μm).

shown to cause hepatocellular carcinoma in susceptible strains of laboratory mice [10] and to promote chemically initiated liver tumors [11]. The link between infection and colon cancer is less clear. There are examples of intestinal infection in animals leading to epithelial cell hyperproliferation and tumor promotion. The aromatic amine 3,2'-dimethyl-4-aminobiphenyl causes urinary bladder tumors in hamsters. When administered to hamsters that have proliferative enteritis, this chemical caused tumors in the small intestine and in the colon [12]. Although infection was suspected as the cause of the enteritis, the agent was not identified. Infection with *Salmonella typhimurium* in laboratory mice [13] and with the obligate intracellular bacterial pathogen *Lawsonia intracellularis* in many species of animals [14] has also been associated with intestinal epithelial hyper-

proliferation, a known biomarker for cancer risk. Infection with these agents has not yet been associated with tumorigenesis, but transmissible murine colonic hyperplasia caused by *C. rodentium* infection promotes colon tumor development in mice administered the carcinogen DMH [3].

In this study, we have demonstrated that bacterial infection promotes colonic adenomas in Min mice. Gould and Dove [15] have reported that environmental factors influence tumorigenesis in the colon but not in the small intestine of Min mice. This was determined by grafting fetal intestinal tissue to an ectopic site. Small intestinal grafts developed tumors at a rate similar to that observed in situ, but no tumors were observed in ectopic colonic grafts. It remains to be determined whether the presence of microbiota is required for colon tumorigenesis

Table 1. Number and location of colonic adenomas in *Citrobacter rodentium*-infected ($n = 15$) and uninfected ($n = 15$) Min mice.

Location	No. of adenomas		Distance to the anus, mm ^a	
	Uninfected mice	Infected mice	Uninfected mice	Infected mice
Colon	0.8 ± 0.2 ^b	2.8 ± 0.7 ^b	30.4 ± 3.2 ^c	16.6 ± 2.2 ^c
Cecum	2.0 ± 0.4	1.8 ± 0.3	ND	ND
Ileum ^d	9.1 ± 1.0	7.2 ± 1.0	ND	ND

NOTE. Values are mean ± SE. ND, not determined.

^a Distance from center of adenoma to anus.^b The difference between the no. of colonic adenomas in infected and uninfected Min mice was significant ($P < .05$). No adenomas were seen in infected ($n = 12$) or uninfected ($n = 12$) wild-type mice.^c The difference between the distance to the anus in infected and uninfected Min mice was significant ($P < .001$).^d Distal 10 cm.

in Min mice; however, infection with *C. rodentium* is sufficient to promote colon tumor development. In contrast to *H. pylori* infection, *C. rodentium* causes a self-limiting condition of epithelial hyperproliferation without an appreciable inflammatory infiltrate. Further studies are needed to determine the relative contributions of cytokinetic alterations and somatic mutations to tumor promotion in this system.

Although *C. rodentium* is not a human pathogen, the bacterial genes required for infection and presumably for the induction of epithelial cell hyperplasia are also present in the human pathogens EPEC and EHEC. The cytokinetics of EPEC infection in the small intestine of children has been studied [16]. Duodenal crypts from infected children were 2 times longer than and had more than twice as many dividing cells as crypts from control individuals. These alterations are remarkably similar to those seen in *C. rodentium*-infected mice [1]. It remains to be determined if EHEC or other bacterial pathogens can cause similar alterations of epithelial cell cytokinetics in the colon.

Our results demonstrate that *C. rodentium* infection promotes adenoma formation in the colon of Min mice. We hypothesize that promotion is due to the hyperproliferative state induced by *C. rodentium* infection. Although increased COX-2 expression occurs early in a mouse model of colitis-associated colorectal cancer [8], COX-2 expression was not detected in colonic tissue from *C. rodentium*-infected mice 10 days after inoculation. This raises the possibility that COX-2 may not be involved in the earliest stages of colon tumor promotion in Min mice. Alternatively, our immunohistochemistry method may not have sufficient sensitivity to detect COX-2 protein in preneoplastic

lesions. In any case, these results must be reconciled with the fact that COX-2 inhibitors prevent tumor development [6]. Further characterization of the molecular mechanisms involved in the induction of hyperplasia by *C. rodentium* will lead to a better understanding of how infection promotes colonic tumorigenesis. It remains to be determined whether infectious colitis is a risk factor for colon cancer in people. The model we have developed provides a novel in vivo system to further explore this provocative possibility.

References

- Barthold SW. Autoradiographic cytokinetics of colonic mucosal hyperplasia in mice. *Cancer Res* 1979;39:24–9.
- Barthold SW, Coleman GL, Jacoby RO, Livestone EM, Jonas AM. Transmissible murine colonic hyperplasia. *Vet Pathol* 1978;15:223–36.
- Barthold SW, Jonas AM. Morphogenesis of early 1,2-dimethylhydrazine-induced lesions and latent period reduction of colon carcinogenesis in mice by a variant of *Citrobacter freundii*. *Cancer Res* 1977;37:4352–60.
- Lupercio SA, Schauer DB. Molecular pathogenesis of *Citrobacter rodentium* and transmissible murine colonic hyperplasia. *Microbes Infect* 2001;3:1–8.
- Moser AR, Luongo C, Gould KA, McNeley MK, Shoemaker AR, Dove WF. *Apc*^{Min}: a mouse model for intestinal and mammary tumorigenesis. *Eur J Cancer* 1995;31A:1061–4.
- Taketo MM. Cyclooxygenase-2 inhibitors in tumorigenesis (part II). *J Natl Cancer Inst* 1998;90:1609–20.
- Luongo C, Moser AR, Gledhill S, Dove WF. Loss of *Apc*⁺ in intestinal adenomas from Min mice. *Cancer Res* 1994;54:5947–52.
- Shattuck-Brandt RL, Varilek GW, Radhika A, Yang F, Washington MK, DuBois RN. Cyclooxygenase 2 expression is increased in the stroma of colon carcinomas from IL-10^(-/-) mice. *Gastroenterology* 2000;118:337–45.
- Parsonnet J. Bacterial infection as a cause of cancer. *Environ Health Perspect* 1995;103(Suppl 8):263–8.
- Fox JG, Dewhirst FE, Tully JG, et al. *Helicobacter hepaticus* sp. nov., a microaerophilic bacterium isolated from livers and intestinal mucosal scrapings from mice. *J Clin Microbiol* 1994;32:1238–45.
- Diwan BA, Ward JM, Ramljak D, Anderson LM. Promotion by *Helicobacter hepaticus*-induced hepatitis of hepatic tumors initiated by *N*-nitrosodimethylamine in male A/JCr mice. *Toxicol Pathol* 1997;25:597–605.
- Williams GH, Chandrasekaran V, Katayama S, Weisburger JH. Carcinogenicity of 3-methyl-2-naphthylamine and 2,3'-dimethyl-4-aminobiphenyl to the bladder and gastrointestinal tract of the Syrian golden hamster with atypical proliferative enteritis. *J Natl Cancer Inst* 1981;67:481–8.
- Abrams GD, Schneider H, Formal SB, Spintz H. Cellular renewal and mucosal morphology in experimental enteritis. *Lab Invest* 1963;12:1241–8.
- McOrist S, Gebhart CJ, Lawson GH. Enterocyte proliferation and intracellular bacteria in animals. *Gut* 1994;35:1483–6.
- Gould KA, Dove WF. Action of *Min* and *Mom1* on neoplasia in ectopic intestinal grafts. *Cell Growth Differ* 1996;7:1361–8.
- Savidge TC, Shmakov AN, Walker-Smith JA, Phillips AD. Epithelial cell proliferation in childhood enteropathies. *Gut* 1996;39:185–93.